



# Cervical Epidural Block for Perioperative Use

Dr. Robert M Raw MD

MBChB(Pret), MPraxMed(Pret), MFGP(SA), DA(SA), FCA(SA).

Professor of Anesthesia to 2016

Editor of Regional-Anesthesia.Com

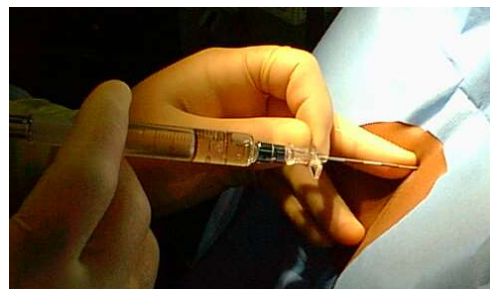[rob-raw@outlook.com](mailto:rob-raw@outlook.com)

(v1-1999). Revised 2020-1-8. 7610 words

© Copyright owned by Regional-Anesthesia.Com LLC. 2177 Port Talbot pl, Coralville, IA52241, USA

## INDEX:

1. Introduction.
2. Anatomy of the cervical epidural space.
3. Indications and uses for cervical epidural block.
4. Contra-indications to cervical epidural block.
5. Complications of the cervical epidural block.
6. Cardiovascular effects of blocked T1-4 spinal segments.
7. Insertion technique for cervical epidural block.
8. Local Anesthetic Toxicity, with cervical epidural blocks.
9. Conclusion.



## INTRODUCTION

“Cervical” epidural nerve blocks are typically inserted between vertebral levels C5 and T4 and are more correctly called cervico-thoracic epidural nerve blocks. The most common insertion point is C7-T1.

Cervical epidurals are unique because they are done *above* the termination of the spinal cord and in the distribution of the Phrenic nerve (C3,4,5,6). This places the spinal cord at risk of needle injury. When lumbar epidural blocks accidentally develop into “total spinal blocks” the patient commonly becomes unable to breathe. It may accordingly be expected that an intentional cervical epidural would be dangerous and cause apnoea. It does not. This lecture will review cervical epidurals.

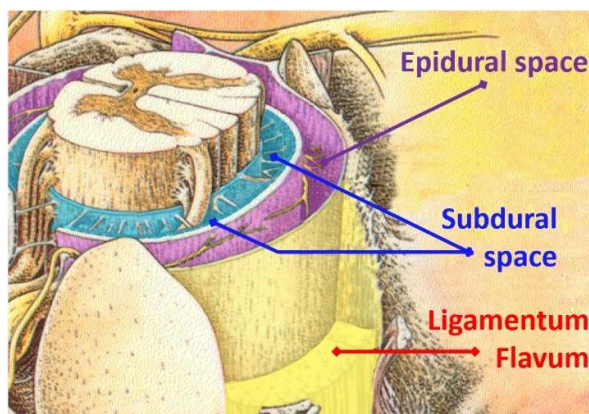
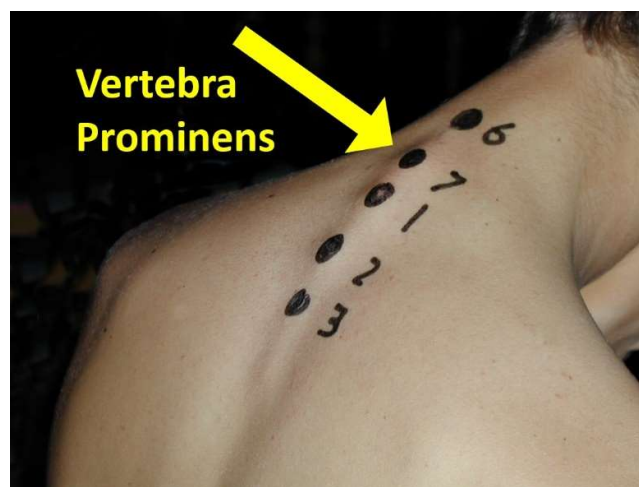Quinke described epidural anaesthesia in 1891. Dogliotti described segmental epidural anaesthesia, in 1931, with the concept that the volume injected determined the extent of segments blocked, and that the site of injection also determined the segments blocked. Epidural blockade maintained with catheter-infusions was described in 1942. Cervical epidurals used for surgery were occasionally done for a long time, and were reviewed in 1984 for use in head and neck surgery<sup>1</sup>. Cervical epidurals have never been so widely performed, as to be part of basic anesthesia skills. Cervical epidurals to date, tend strongly to be performed only by leading notable experts within the regional anesthesia community. Around the world the block is predominantly performed by chronic pain physicians injecting steroids via transforaminal approaches<sup>5</sup>. This chapter is intended to focus on the use of this block in the perioperative period injecting local anesthetic drugs via midline approaches.

**Note:** This lecture is aimed at the anesthesia and acute analgesia uses of cervical epidural injections. Although there will references made to **steroid cervical epidural injections** for chronic pain, this lecture is **not** discussing transforaminal approach techniques, nor the merits and indications for steroid injections.

Attention, academic supporters, sponsors and advertisers. This banner space on page #1 of this document, is available for advertising on the web-available free copies of this lecture, at **Regional-Anesthesia.Com**. You can also place a dynamic link on the banner, to your website. If interested contact [editor@regional-anesthesia.com](mailto:editor@regional-anesthesia.com) for information.

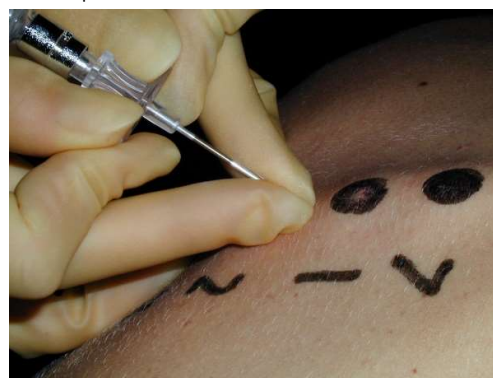
## ANATOMY of the CERVICAL EPIDURAL SPACE

Generally, cervical epidural anatomy is similar to the familiar lumbar region with some notable differences. The dorsal processes from about C5 down to about T3 are sufficiently horizontal and narrow enough, to provide wide passage between them for easy midline access to the epidural space. Above and below that, the dorsal processes are angled too steeply downwards making the midline approach to the epidural space there, very difficult. The dorsal process of C7 is uniquely well developed, is nearly fully horizontal when the neck flexes and the person is sitting upright. The C7 dorsal process, or spinous process tends to bulge prominently under the skin and is called the Vertebra Prominens landmark. The Vertebra Prominens allows easy identification of the C6-7 and C7-T1 interspaces. Interspace C6-7 and C7-T1 are the recommended vertebral interspaces to use. Interspaces at C5-6, T1-2 and even T2-3 are also reasonably easy to use, and may be more appropriate choices for certain areas of surgery.

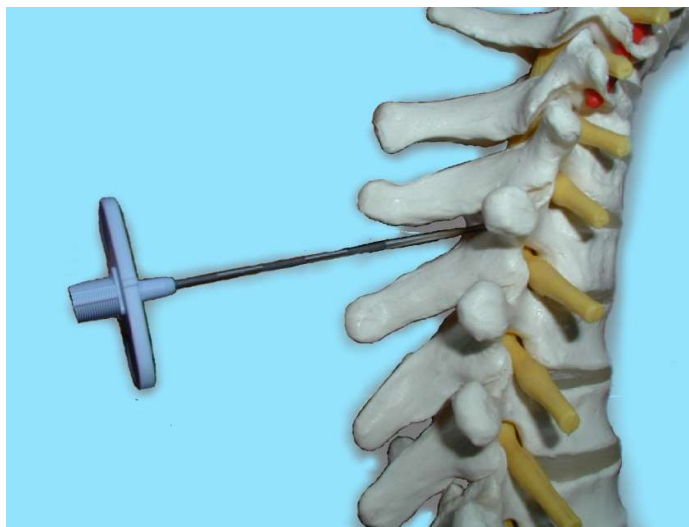


The Ligamentum Flavum is less well developed in the cervical region than in midlumbar region, but is still mostly recognisable with epidural puncture as a tactile “POP” when advancing the needle through it<sup>2</sup>. The ligamentum frequently also fails to fuse in the dorsal midline in those higher spinal canal segments. That will not affect the loss of resistance (LOR) sign of epidural space resistance, but may remove any “popping” feeling in the needle, as it enters the epidural space. That may increase the potential to accidentally insert the epidural needle too deep,

and into the spinal cord, compared to when doing low lumbar epidural blocks. In about 5% of cases a Loss of Resistance (LOR) is felt on entering the epidural space during needle insertion, without any preceding perceived tactile “POP” of the Ligamentum Flavum. The Ligamentum Flavum may be very tough close to its bony attachments, above and below, and occasionally great resistance to needle advancement is felt with the risk of a sudden lunge with the Tuohy needle after passing through the ligament. So, a good needle-holding technique must be used to prevent any amount of needle forward lunging when any resistance is overcome, while advancing the needle. Also, there may be a zone of soft tissue offering no resistance to passage of the Tuohy needle between the Supraspinous ligament and the Interspinous ligament. This space offers a false apparent *Loss of Resistance* to injection of air or saline and can be confused with the actual epidural space. A false *Loss of Resistance* may also be due to the Tuohy needle deviating slightly off midline, and exiting the narrow Interspinous ligament and entering muscle. See the discussion on technique.



The epidural space is fairly deep, and ranges from 4 to 7 cm deep to the skin the skin. Aldrete<sup>3</sup> analysed 100 patients MRI scans. The longest Dorsal Skin to Epidural Space (DSES) was at C6-7 and C7-T1, with a mean depth of 5.7 cm. T1-2 averaged 5.4 cm deep from the skin, and T2-3 averaged 4.7 cm deep from the skin. Aldrete found the *width* of the epidural space in the posterior midline as 3mm at level C6-7, 4mm at level C7-T1, 5mm at level T1-2, and 4mm at level T2-3. Lin<sup>4</sup> made clinical measurements with a flexed neck (during insertion of epidural catheter) showed a Dorsal Skin to



Epidural Space (DSES) at C7-T1 to be 4.8mm wide. Other researchers have shown the width of the actual epidural space in the midline is 5-6mm in the mid-lumbar region, but is only 2mm in the C3-6 zones, and depth increases slightly to 3.5mm at T1-2. These figures show that the width of the cervical epidural space is double the distance in the neck-flexed position compared to the neck-straight position. The figures are varied between researchers, due to them using measuring techniques on different subjects.

The epidural vein plexus is best developed *laterally* and least developed in the posterior midline. The veins are valveless and connect to the cerebral sinuses. It is possible for a small dose of local anaesthetic to provoke convulsions if injected into an epidural vein in the neck region, with retrograde flow to the brain (author experience).

## INDICATIONS and USES: CERVICAL EPIDURAL BLOCK <sup>5</sup>.

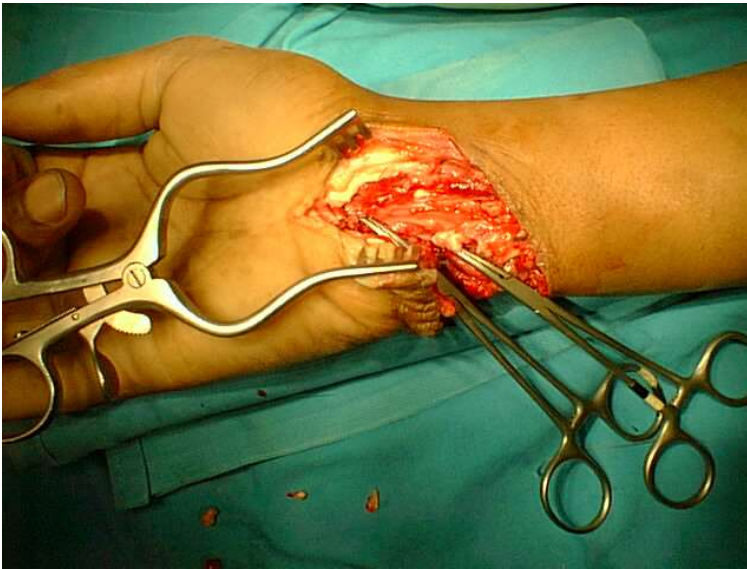The cervical epidural block can sometimes be used as the sole anaesthetic. Around the world the most common surgical indications are carotid endarterectomy and upper limb surgeries<sup>5,6</sup>. It can be used for analgesia after general anaesthesia, and also be used for chronic pain control. Cervico-thoracic epidurals have been used for very diverse reasons. Any need for anaesthesia or analgesia in the C3 to T6 dermatomes may be considered possible indications for cervical epidural blocks. A brief list of possible applications is for thyroid surgery<sup>7,8</sup>, neck lymph-block dissection, arm orthopaedic surgery<sup>9,10</sup>, arm re-anastomosis, mastectomy, Carotid Endarterectomy<sup>11,12</sup>, steroid injection for neck pain and cervical radiculopathy<sup>13</sup>, analgesia after open heart coronary surgery<sup>14</sup>, analgesia after thoracoscopic sympathectomy, treatment of Rheumatoid arthritis associated cutaneous vasculitis<sup>15</sup>, cervico-genic headache<sup>16</sup>, unstable angina pectoris<sup>17,18</sup>, sole anaesthetic for thoroscopic repair of pneumothorax<sup>19</sup>, awake thoracic surgery<sup>20</sup>, cervicobrachialgia (50 cases)<sup>21</sup>, home pain control in a child with cancer<sup>22</sup>, chronic head and neck pain (141 blocks in 45 patients)<sup>23</sup>, prevent broncho-carinal reflexes (but not laryngo-tracheal) reflexes<sup>24</sup>, and breast surgery<sup>25</sup>. In the Takeshima study<sup>26</sup>, the cervical epidural block was given in addition to the general anesthetic for radical mastectomy.

A rare prospective comparative trial randomized 75 patients between continuous interscalene block and continuous cervical epidural block<sup>27</sup>. In each group 0.2% ropivacaine infusions were used for postoperative analgesia, following shoulder surgery performed under general anesthesia. Both groups achieved good analgesia, but on summation of outcomes the interscalene block was modestly better, mainly in terms of analgesia and patient satisfaction despite causing more measured respiratory changes than the epidural block.





Wenk in 2017, reported on a retrospective study of the feasibility for 39 patients to undergo *awake* surgery for mastectomy, under cervical epidural<sup>28</sup>. The full success rate was 66.7% (n26). Patients who



needed supplementary analgesia were 17.9 % (n7). All the rest need a general anesthetic. Wenk emphasized that a major limiting factor for this block, is that such a nerve block is *not a basic skill block known* to commonly qualified anaesthesiologists, nor an easily learned block by someone generally unfamiliar with epidural blocks. Wenk's study is however severely flawed, as no patient extent-of-block was described, nor the drug-doses and volumes used, nor are the exact surgeries done described. Breast cancer surgery spans a very wide range of

magnitudes, with many different tissues that can be excised or not. Specific supplementary nerve blocks need to be done for specific portions of the surgery, such as excision of all pectoral muscles and exploration of the axilla. It is a very wide span of dermatomal segments for a single epidural block to cover. (Refer to [www. Regional-Anesthesia.Com](http://www.Regional-Anesthesia.Com) or google for Review 19RCSBAA, for a full description of regional anesthesia options for all breast surgeries, and the relevant applicable breast region anatomy).

Paliwal reported an off-pump awake coronary artery bypass grafting under high thoracic epidural inserted at T2-3 has been successfully done many times<sup>29</sup>. They were correctly cautious in timing epidural catheter insertion and removal, to the administration of anti-coagulants. Paliwal references other similar case reports. There are studies suggestive that high thoracic epidural anesthesia improves failing heart function and health, and also improve myocardial ischemia. (This is not an aspect for review in this study).

One retrospective study suggested cervical epidural used for laryngeal and hypopharyngeal surgery improves cancer-free outcomes<sup>30</sup>. That claim is too wild to be taken as a factual outcome, until large-number prospective randomized studies are done, and is insufficient to base practice change recommendations upon.

## CONTRA-INDICATIONS for CERVICAL EPIDURAL BLOCKS

Contra-indications are generally logical, and common to the contra-indications for all epidural anaesthetics. In particular, contra-indications are nearby sepsis, coagulopathy, fixed cardiac output states, lack of expertise in doing lumbar epidural anaesthesia, and lack of general anaesthesia resuscitative skills.



## COMPLICATIONS

A feature of Cervico-thoracic epidural complications is how few complications are described in the scientific literature. It seems the risk of a serious problem arising is very low, and authors have speculated that this is due to the high level of skill of the practitioners generally doing epidural nerve blocks above the low lumbar region.

Serious sequelae attributed to cervical epidural injection are largely limited to few single-case reports. Spontaneous cervical haematomata and abscesses (unrelated to any intervention) although uncommon, are very well recorded in the literature due to their seriousness. The scarcity of reported similar hematoma complications after cervical epidural blocks is not adequately explainable by arguing that relatively few cervico-thoracic epidurals are done, as these blocks have had their proponents for over 40 years and the benefits of the technique is well reported generally. One thus can only guess the hematoma risk after cervical epidural block is generally low.

### 1. Respiratory difficulties<sup>5</sup>.

Clearly total motor blockade of both **Phrenic Nerves** would result in inability to breath, and this has been reported, all be it infrequently<sup>5</sup>. What is remarkable is that intentional epidural in the neck seems *unassociated* with symptomatic Phrenic nerve block generally. The phrenic nerves come from spinal segmental levels C3-4-5. The Phrenic nerve seems more resistant to nerve block in the epidural space than any other motor nerve of the body at other sites. It is also possible that the anterior abdominal wall muscles are mostly unblocked with cervical epidural blocks and their preservation facilitates some secondary accessory muscle respiratory function. It is noteworthy that, a total spinal block injected in the lumbar region causing phrenic nerve palsy, causes absolute apnoea with the added fact that the abdominal wall is paralyzed too.

There is however a cervical epidural study that used 0.375% bupivacaine or 1.5% mepivacaine in two groups, where on fluoroscopy there was marked loss of diaphragmatic function, but without respiratory distress<sup>31</sup>. They also observed that the greater the degree of loss of diaphragmatic excursion, the greater the clinically apparent paradoxical abdominal compensatory movement was.

Cervical epidurals have been done with 2% lignocaine, which normally blocks motor fibres very effectively, and the patients maintained adequate ventilation<sup>32, 33</sup>. Abundant reported experience has however shown using Bupivacaine at modest dilutions of 0.375% or less is totally safe. Ropivacaine 0.4 to 0.5% or less would seem even better suited for cervical epidural nerve block. There are studies of intentional cervical epidural blockade that have shown a measurable, and mostly insignificant, effect on ventilatory parameters using virtually all local anaesthetics available, in a range of concentrations. The only recorded evidence of ventilatory difficulty, were case reports of severe respiratory cripples, where 0.5% Bupivacaine was used and some patients blood gas parameters altered sufficiently for concern, but not fatally so. Other proponents of cervical epidural anaesthesia in fact consider the respiratory cripple an indicated patient for using this anaesthetic technique in order to avoid general anesthesia and large opiate doses. Clearly, anesthesia decision making can be complex. This author would still caution against doing cervical epidural blocks in patients with marked respiratory compromise, for the sake of maximally preserving bilateral phrenic nerve function.

Capdevilla<sup>34</sup> studied 10 patients undergoing hand surgery solely under cervical epidural analgesia. Spirometric tests, blood gas measurement, and ultrasonographic assessment of



diaphragmatic movement was done. Bupivacaine doses of 0.37% and 0.25% were studied. He observed a statistically significant, but clinically insignificant change in blood gas values. Mean PaCO<sub>2</sub> increased from 35.2 to 39.3 mmHg and PaSO<sub>2</sub> declined to 98%. The clinically significant spirometric changes were only seen in forced manoeuvres. Diaphragmatic excursion changes were only observable during vital capacity breaths. The cervical epidural technique allowed excellent rehabilitation of the operated hands with painless voluntary movements being possible, and no detrimental outcome occurred. He however, concluded the cervical epidural anaesthesia was not to be recommended, but it must be noted he did not compare the study group to a control group having general anaesthesia with opiate analgesia post-operatively.

Nystrom<sup>35</sup> studied 16 patients undergoing major arm reconstructive surgery with continuous cervical epidural infusions for 6 days and found only very favourable results and outcomes.

Stevens<sup>36</sup> administered 2% lignocaine in the cervical epidural region in 15 patients with lung diseases undergoing carotid endarterectomy or steroid injection for painful necks. He injected fifteen millilitres of 2% lignocaine injected at the C7-T1 inter-space. Blocked dermatomes spanned a range from C2 to T12, with a mean of C3-T8. It took 20 to 40 minutes to achieve maximal disturbances in ventilation. FVC and FEV1 fell 12 – 16%. but blood gasses, Maximum Inspiratory Pressure and arterial blood O<sub>2</sub> saturation did not change. Only one patient in this study was considered to experience clinically significant nerve blocking of the Phrenic nerve.

It must be noted in all these studies results were compared with same patient pre-surgery baselines. The studies were specifically not controlled against alternate regional technique (e.g. deep cervical plexus block, or brachial plexus blocks, with and without sedation). It is also important to decide whether any statistical changes seen, were clinically significant as well.

Huang from Taiwan studied 50 young adult patients undergoing upper limb orthopaedic surgery<sup>37</sup>. Epidural catheters were inserted at the C7-T1 interspace and advanced cranial for 12 cm distance. The dose of local anesthetic was 12 ml of 2% lidocaine with epinephrine. Anesthesia levels produced were C3-T3. Mild respiratory acidosis developed with PaCO<sub>2</sub> levels of 48 – 44 mmHg. FEV1 was decreased up to 18%. The researcher concluded patients with normal good health could tolerate those changes very well.

*In summary; blocking the Phrenic Nerve with a cervical epidural should not be a regular problem because;*

- Total Phrenic Nerve blockade has never been specifically documented with any intentional Cervical epidural.
- There is clinical and anecdotal evidence that the Phrenic Nerve is uniquely in the body, *relatively resistant to nerve blockade*.
- One can use motor-sparing local anaesthetics in slight dilution such as Bupivacaine at 0.375% or Ropivacaine at 0.4% or less.
- One can omit 2% lignocaine test doses.

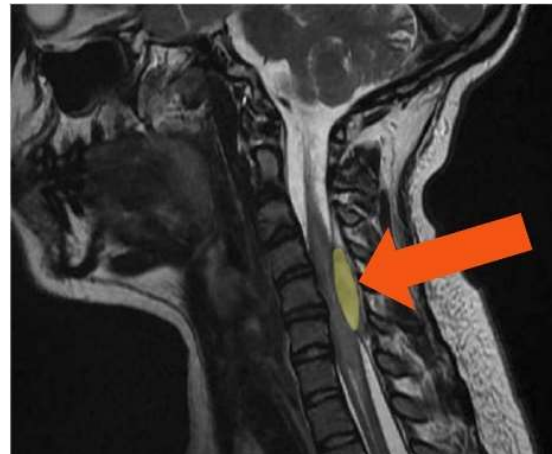This author would be loath to use a cervical epidural block in a respiratory cripple. However, Wittich<sup>38</sup> in his 1984 review felt the cervical epidural used for awake surgery was a relatively indicated technique to be used in preference to general anesthesia for respiratory cripples, at that time. This author would however strongly favour using the many phrenic nerve preserve alternative regional anesthesia techniques, specific for any surgery in the upper body. Cervical Epidural block is but one of many available options.



## 2. Hematoma of the epidural space.

Iatrogenic cervical epidural haematoma is only described very rarely<sup>39</sup>. The risk of developing a hematoma, has been suggested to be lower than in the lumbar region, as venous pressure is much lower in the neck than in the lumbar region. It is perceivable that maybe cervical hematomas after an intervention only develop if a higher pressure small artery or arteriole is the injured blood vessel. Any haematoma ever observed in the cervical epidural region, is more likely to have occurred spontaneous than be associated with a regional anesthesia intervention.

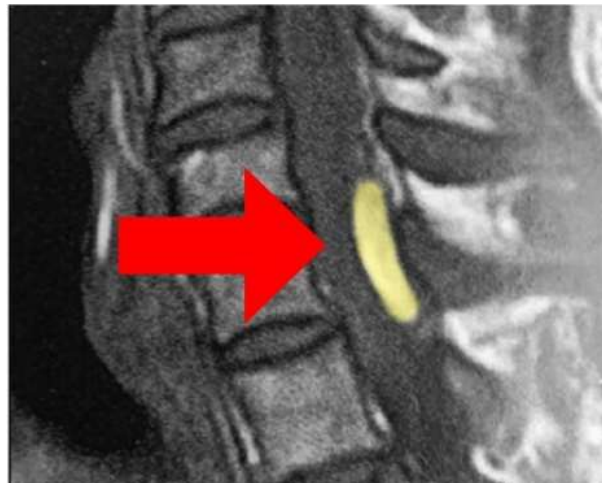
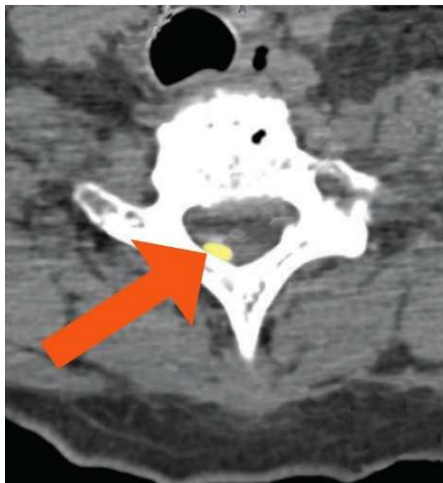The symptoms of cervical epidural hematomas whether secondary to an epidural, or being spontaneous are fairly consistent<sup>40, 41</sup>. Severe neck pain is the usual first and prominent sign followed soon by quadriparesis and urgency of micturition. The neck pain can radiate into both upper extremities. In one case the time interval from the first symptom to loss of walking strength to 3/5 level, took 6 days to develop<sup>42</sup>. It took that patient one year to recover fully although he could walk much better within 2 days, after urgent drainage surgery.



In another case, severe neck pain and upper limb paralysis developed within 30 minutes of the cervical epidural injection<sup>43</sup>.

Sometimes clinical weakness can be dominantly, but not exclusively, unilateral and can cause a misdiagnosis of a stroke, with then mistaken initiation of anticoagulant therapy<sup>44</sup>. The seriousness of the limb weakness can result in overlooking the critical signs of neck pain with neck movement limitations.

One aged patient, 80 years old, developed severe neck pain and total paralysis of the legs 2 hours after receiving a cervical epidural<sup>45</sup>. His treatment was delayed due to being transferred to another hospital, and he showed some recovery. It was decided to treat him non-surgically. The MRI showed hematoma from C4 to T1. After a month he was fully



Cervical epidural hematoma.

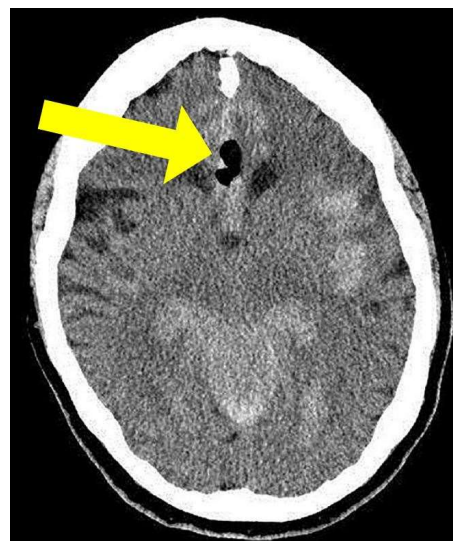

clinically recovered and the MRI of his neck spine was fully normal. This is the only known case of spontaneous recovery from a seeming cervical epidural hematoma following a cervical epidural block.

The advised best times to operate to achieve best outcomes have been said to be within eight hours from first symptoms to within 48 hours from the first symptoms. Surgery is always maximally urgent, and should not be delayed. The big challenge is to make the timely correct diagnosis. Always be very suspicious about neck pain developing after cervical epidural injections.

### 3. Pneumocephalus:

When using a Loss of Resistance to injection (LOR) technique to help identify the epidural space with the tip of the needle, there is always a possibility of first puncturing the subdural space, before loss of resistance is detected. Then the contents of the syringe will have been injected into the subdural space. Injecting a few millilitres of saline subdural is harmless. Injecting a few millilitres of air is also harmless, provided the air stays in the spinal canal region. If the attempted epidural was low, e.g. lumbar, and the patient remains supine the air ultimately absorbs and is without symptoms. Procedures where the injection is closer to the cranium and the patient is seated during the procedure, and or ambulates immediately afterwards, the subdural air ascends readily into a brain CSF cistern, where it causes severe headache<sup>46</sup>.



Accordingly, it is strongly recommended that a pure loss of resistance to air injection technique not be used for high thoracic and cervical epidural blocks.

### 4. Provocation of hyperalgesia<sup>47</sup>.

Field reported three cases with near identical clinical experiences. The three patients had marked neck pain and limb pain associated with relatively severe pathological tissue or bone protrusion into the spinal canal matching with the dermatomes of pain complaints. Upon needle insertion for steroid injection into the epidural space, *immediate* increased neck and arm pain occurred. Each patient soon developed marked *allodynia* in the affected limb that lasted many days. Ultimately all the patients were moderately better off for having undergone the steroid injections. Note instant neck pain upon epidural needle insertion is not a sign of spinal canal hematoma. Spinal canal hematoma develops later after the passing of a few hours to a few days. The instant-pain with needle insertion or injection, does however indicate the patient's severity of hyperalgesic pain, as does the additional remote allodynia accompanying that. Recognizing this hyperalgesia syndrome, invites additional medical therapy for allodynia be administered to the patient, such as IV ketamine.



5. Epidural abscess in the cervical region.

The presentation can follow the epidural block as soon as 48 hours later<sup>48</sup>. Neck pain is prominent, soon followed by weakness in all four limbs, with respiratory compromise. The patient will be febrile and have blood evidence of infection. Abscess drainage and antibiotic therapy for the patient is very urgently needed.

6. Hypotension.

A segmental epidural in this region despite blocking cardiac accelerator fibres, seldom causes bradycardia requiring anti-muscarinic therapy. Hypotension seems less of a problem with cervical epidurals, than that seen with extensive lumbar epidurals anaesthesia due to the short segmental spread of cervical epidural anaesthesia using smaller drug volumes, and the preservation of vascular tone in the legs.

7. Direct Spinal cord damage.

Lancing of the spinal cord in the Cervical region with resulting damage from the Tuohy needle has rarely been suspected. Hodges<sup>49</sup> in 1998 described for the first time two patients experiencing possible chord damage after steroid injections for neck pain. Pain and new neurological fallout developed within 24 hours. The lancing of the cord occurred despite the use of fluoroscopy. Giebler<sup>50</sup> studied 4185 patients having high thoracic epidurals. The overall incidence of dural puncture was 0.7% (n= 30), post-anaesthetic radicular pain 0.3% which all responded to catheter removal, and no case of symptomatic cord injury occurred in that study. There was a lower incidence of complications in the high thoracic epidural (T3-7 insertions) group compared in the low thoracic epidural group (T8-12 insertions). Radiology literature describes a case where during attempted cervical myelogram, the chord was perforated but without sequelae.

It must also be noted that intentional Cervical *intrathecal* anaesthesia is a described. Also, there is a known surgical technique of inserting a large needle into the spinal cord, to draining syringomyelia by catheter in awake patients. The cord itself is insensate for pain. This supports the impression that cervical cord damage is extremely rare, and also that chord lancing may not result in discernible damage or catastrophic necessarily. *Injection* of drugs or substance into the spinal cord is however, catastrophic and often fatal.

8. Post-Dural-Puncture-Headache (PDPH).

This can occur if unintended dural puncture with CSF leakage occurs. It responds to a lumbar epidural blood patch, if needed<sup>51</sup>.

9. OTHER:

Other rare events have been described occurring in chronological association with cervical epidural injections. Association does not prove causation. Due to their rarity, and due to no rational explanation to link them to the epidural injection they cannot be listed as true risks and true complications of cervical epidural blocks. Extensive haemorrhagic stroke



has occurred once in time association with a cervical epidural being performed<sup>52</sup>. Vertebral artery injury is rare, and only in context of transforaminal cervical epidural injections<sup>53</sup>.

**In summary**, dural puncture using cautious small advancing movements usually enters the subarachnoid space without cord lancing. Entry into the subarachnoid space (dural puncture) alone, by needle or catheter is not damaging. It is necessary to advance through the subarachnoid space to lance the chord. Apparently, chord lancing alone, also does not always lead to symptomatic chord damage. *What is extremely damaging after needle puncture of the cord, is to then inject drug or substance into the cord. That is the event to most seek to avoid.*

*Lastly what is very important is that surgery to relieve compression from a haematoma, should the complication arise, is an extreme emergency as is any epidural hematoma. If hematoma draining surgery delayed beyond 8 hours from the first symptom, full recovery may be impossible and only partial improvements will be had at best permanent quadriplegia is likely. Delays reaching 48 hours after first symptoms will be highly likely associated with permanence of the worst symptoms like quadriplegia.*

## CARDIOVASCULAR EFFECTS OF T1-4 EPIDURAL BLOCKADE.

The understanding of these effects has grown in recent years and is complex, and dependant on the effects of other epidural segments simultaneously blocked. The net result is variable. This paragraph summarizes the paragraph in Cousin's book "Neural blockade"<sup>54</sup>. The sympathetic nerve supply to the heart originates from T1-4 and stimulates chronotropy and inotropy. Teaching has always been that T1-4 blockade causes a severe bradycardia. It seems however, that neural blockade of T1-4 reduces sympathetic effects in only 80% of patients.

The net effect of a T1-4 epidural blockade, as part of the cervical epidural block, depends on;

1. Whether the splanchnic sympathetic fibres are also blocked or not (T6-L1), which supplies neurogenic control to the adrenal gland and splanchnic vasoconstrictor fibres (the splanchnic bed has a very large potential vascular capacity)
2. Whether the lower limb vasoconstrictor fibres (T11/12-L4) are blocked.
3. Whether the pre-block intra-vascular volume is depleted.
4. The systemic absorption of local anaesthetic is sufficient to depress myocardial function. The same blood levels that 20 ml Bupivacaine 0.5% administered in the human lumbar epidural space produces, reduces myocardial contractility about 15% in animal research models. Smaller amounts of bupivacaine will produce proportionately less myocardial contractility suppression. Cervical epidurals mostly are only injected with modest amounts of local anesthetic drug.
5. Whether there is over-riding (unopposed) parasympathetic activity at the same time. Parasympathetic control is via the Vagus nerve, which is not blocked by epidural. Zero vagal tone will cause no heart rate changes. Unopposed vagal stimulus will cause profound bradycardia.

Clearly an intentional segmental cervico-thoracic small dose epidural will behave differently from a large dose lumbar epidural extending into the cervical zone of nerve blockade.



Lumbar epidurals extending to above T4 are associated with a 20% fall in Blood pressure. Segmental Cervico-thoracic epidurals have blood pressures that show no change or less than 10% reductions. Also, with segmental cervico-thoracic epidurals the CVP has been shown to increase some times, although it tends to fall with epidurals extending C5 to S5. In summary the cardiovascular effects of segmental cervico-thoracic epidurals are remarkably benign. There are fascinating beneficial effects on myocardial ischaemia which have been reported. (not reviewed in this lecture)

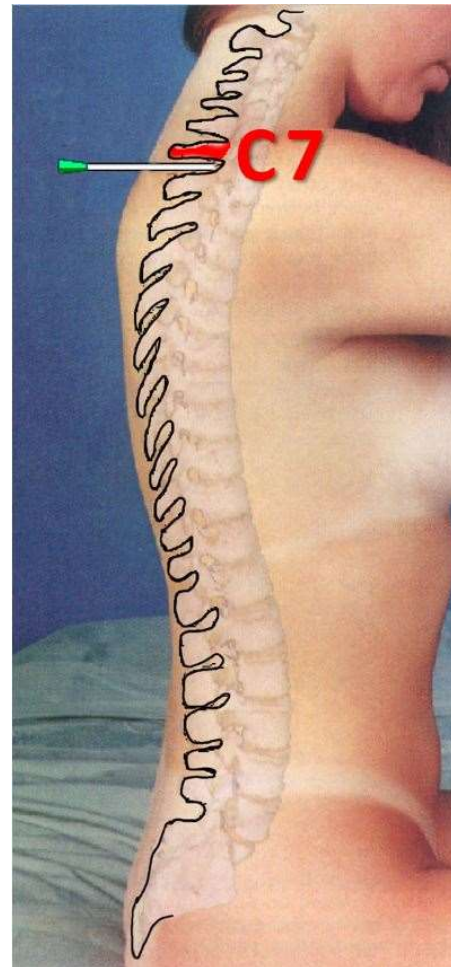
It remains however very important that the anaesthesiologist have vascular access, commence restoration of prior intra-vascular deficits, have airway management facilities at hand, and be able to administer atropin and vasoconstrictors prior to initiating doing a cervico-thoracic epidural block. This rule applies to all epidural nerve blocks.

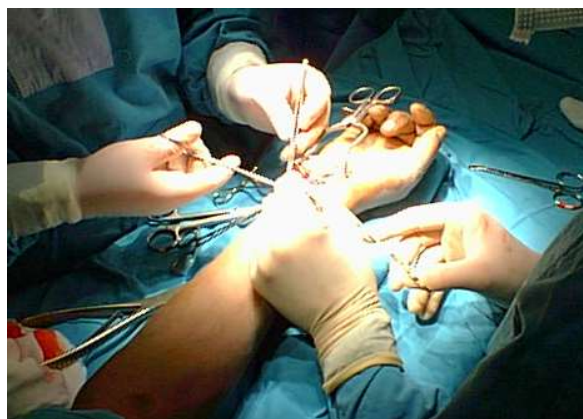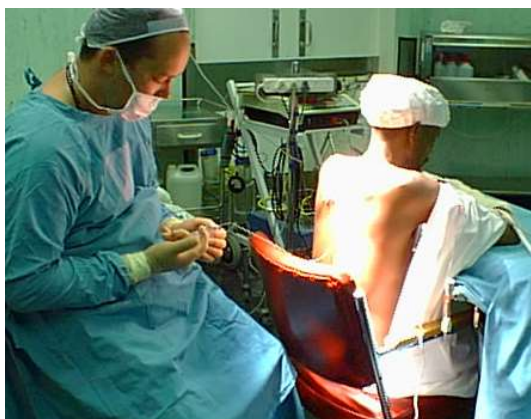## INSERTION TECHNIQUE

The technique is broadly similar to inserting epidural catheters in the low lumbar region with some minor differences.

### 1. POSITIONING.

Cervical Epidural Block (CEB) is done easiest with the patient sitting on a chair, with arms resting in front on an operating-table set to shoulder height. The back must be in a vertical military upright position. The neck must be flexed forward, to a maximum, and the arms must rest on a pillow in front of the patient. This stabilises the patient against swaying during pushing with the epidural needle. The Tuohy needle is kept in the midline and aimed horizontal, or very slightly upwards. The patient is best seated on a normal low chair while the anaesthesiologist may either stand or sit on a high stool. Other workers and the author often use the lateral position because the block is easy enough even in that position (after some experience) and the patient can lie more still. Swaying in the sitting position is a slight distraction. The lateral position also allows the block to be done in the anaesthetised patient.





## 2. THE EPIDURAL SPACE IDENTIFICATION

The epidural space is identified by a combination of;

- The feeling of a popping through the Lig. Flavum (usually felt).
- The loss of resistance to injection of Saline (recommended) or air.
- The hanging drop method is fairly reliable in this “high” position compared to the lower lumbar region in the sitting position. The differential diagnosis when the droplet is drawn inwards, is intravenous placement of the needle. The epidural venous pressure in the sitting position at the C7-T1 level, is usually negative compared to atmospheric air.
- A negative test dose, if done.

If testing for spinal block, do not use more than 1 ml of test dose, and evaluate ability to spread the fingers.

## 3. RECOGNISING THE “FALSE EPIDURAL SPACE”.

This “space” is seen in the lumbar region in 1 to 2 % of cases, but seems to happen in the cervical region in up to 10% of cases. This is more often felt fairly “shallow” and is due to the lack of continuity between the supraspinous and interspinous ligaments. A false epidural space can also be found due the Tuohy needle deviating sufficiently off midline to exit the firm ligament and enter the paravertebral; muscles before the Ligamentum Flavum is encountered. The cervical Interspinous ligament is narrower and less developed in the neck region, compared to the lumbar Interspinous ligament. One challenge is to recognise this “false epidural space” while performing cervical epidural blocks.

The needle tip being within a false epidural space is suggested by a number of signs. The more signs that are present, the more certain the diagnosis will be;

- No preceding Lig. Flavum “pop” is felt as the Tuohy needle advances.
- The epidural space seems closer to skin than expected.
- The epidural catheter will not feed more than 1-2 cm into this “epidural space”.
- No CSF can be aspirated. (positive CSF only diagnoses the needle tip is in the subarachnoid space). (negative CSF 90% excludes the needle tip being intrathecal).



- The saline injected into the “epidural space” offers a very slight resistance that makes the experienced hand suspicious, and feel is slightly “bouncy”. The loss of resistance when injecting into the true epidural space is more emphatic.
- Three or more drops of the LOR saline return from the needle (usually not with true epidural puncture in the neck region).

If most of the above factors are present, then proceed as follows. Apply gentle traction to the catheter and if it EASILY is removable, advance the Tuohy needle again, 1 mm at a time, testing for loss of resistance at each step. Importantly, if the catheter offers any resistance to removal then remove it with the needle and start afresh. Attempting to pull out a catheter via the needle that is resisting removal, can cut the tip of the catheter off, leaving it in the tissues. Reassess the position considered to be the midline. Usually a fresh resistance is felt after advancing the needle 1-2 mm further. There is typically full resistance to injection again. This is reassuring. Proceed until the true epidural space is identified.

#### 4. TEST DOSE

One must be clear what one is testing for. A test can identify (1) intravenous position of catheter-tip, (2) intrathecal position of a catheter tip, (3) whether the patient has allergy for the drugs, and (4) patency of the catheter. Not everything can always be tested with one test-injection formulation. A cervical epidural test dose is limited in some respects. One may have to prioritize concerns, and consider different tests for some considerations.

A test dose done for identifying intravenous (IV) catheter placement can inject 15 micrograms of adrenaline in the test solution, of 1 millilitre. That is supplemental to an aspiration test. No test fully excludes intravenous catheter placement. One must remain cautious about an intravenous needle or catheter tip placement, regardless of whether the patient passed an aspiration test and an adrenaline for tachycardia. The adrenaline test is notoriously fallible and may be omitted if one wishes to restrict fluid volumes injected into the epidural space. Aspiration test should however, always be repeatedly done. Correct technique is to aspirate softly and sustained, and be repeated a few times. Correct technique is not one snappy fast big pull on the plunger with zero pause, before proceeding.

The Lumbar region epidural test solutions usually include a potent local anaesthetic (e.g. 3ml of 2% lignocaine (lidocaine) to test for subarachnoid catheter placement by seeking signs of a spinal block. A lignocaine (Lidocaine) test dose for intrathecal catheter or needle tip placement in the cervical region, *if used*, must be of small volume not exceeding 1 ml. A larger volume may influence the epidural block, which is a small volume block in itself using mildly dilute local anesthetic.

This lecturer does not routinely use an *intrathecal test dose* when doing cervical epidural block, and rather maintains a high level of alertness to manage any complication that may arise rather. Aspirating for blood and CSF via the catheter is however always important. The recommended main dose drugs are too low in dilutions to cause dense nerve paralysis if injected subarachnoid, and are too small in volume to cause systemic toxicity if injected intravenously, usually.

#### 5. EPIDURAL CATHETER INSERTION.

(Author has no trade connections)



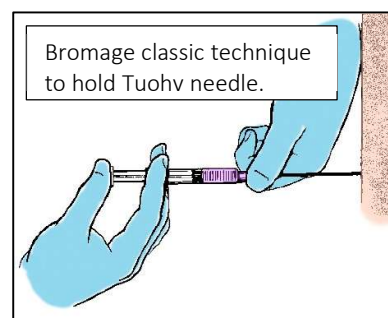
The epidural catheter may be advanced 3 to 4 cm into the epidural space. Using a true ultra-soft-tip catheter is highly recommended. Arrow epidural catheter Flextip<sup>®</sup> is best. The B.Braun soft tip catheters are less soft, but acceptable. It is important to note that the softer the catheter-tip is the more *unlikely* it is that it could advanced beyond the needle within the spinal cord. That is a very important test.

In other words, if an ultra-soft-tip catheter can be easily advanced 3-4 cm beyond the needle, that is the all-important test to exclude a needle being within the spinal cord. All regional anesthesia technical complications can be treated with anesthesiologist skills with no permanent bad outcome, except for an intra-cord injection. A catheter that passes easily is in one of three places; (1) intrathecal, (2) intravenous or (3) epidural, but NOT within the spinal cord.

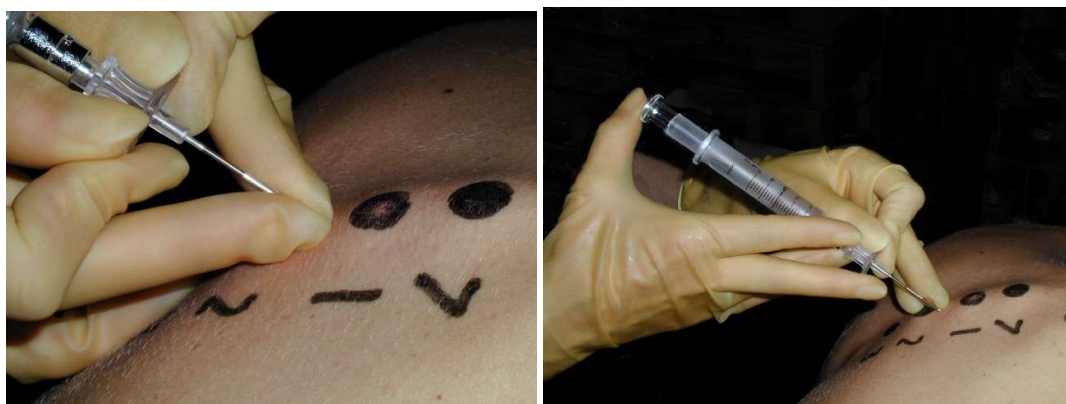Do not forget, an intra-cord injection induced injury is catastrophic and permanent.

#### 6. HOLDING THE TUOHY NEEDLE.

A technique must be used where the needle can be advanced using **firm pressure**, but where the needle is **securely held** so that any sudden loss of tissue resistance will only result in a small needle advancement of 1-2 millimetres at most. The classic Bromage technique with the dorsum of the left hand back, against the patient back is sufficient.



This author prefers a technique securing the needle firmly between the 2 middle fingers flush against the skin, with each hands' thumbs and index fingers holding a wing of the Tuohy needle. This will protect against lancing the cord with an uncontrolled lunge of the needle, if any tissue resistance to needle advancement is unexpectedly overcome. This is the most important technical aspect. Any alternative techniques may also be adequate, provided the operator has an intentional firm grasp of the needle with a hand stabilize against the patient, so as to have firm *control of needle advancement*.



The modern shaft-and-winged needle Tuohy-needle double-point hold technique, with a LOR syringe touch modification.



#### 7. LOSS OF RESISTANCE TO SALINE (or 5% dextrose water)

Loss of Resistance (LOR) to injection to pure normal saline or 5% dextrose water, is recommended, for two reasons. One, the end point is much more obvious than when compared to just using air with a bouncing plunger. Two, the risk of pneumocephalus is avoided. Pneumocephalus is very painful. This author does not recommend the mixed saline-air technique, as it is still possible to inject air into the spinal canal. Also, the need of keeping the mixed air-saline syringe angled downwards to prevent air injection, adds unnecessary technique elements to the procedure.

Pneumocephalus will occur if the injected test-air, is inadvertently injected subdural. The bubbles in the CSF float upwards to enter the brain ventricles, where they cause severe headache. Intrathecal injected air in the cervical region, reaches the brain ventricles very easily as the distance is short and the patient is sitting. By comparison, the risk for pneumocephalus is lower when accidental intrathecal air is injected lumbar in supine patient who stays supine for a few hours.

If a purpose designed LOR syringe is unavailable, a small thin syringe like a 2.5 ml regular syringe can perform well as an alternative LOR syringe. This author has used this for thousands of cases without problems. Larger regular syringes have too much inherent drag between the syringe-cylinder and the rubber-plunger-head to be used as LOR syringes.

#### 8. ULTRASOUND GUIDANCE.

The sonographic anatomy of the neck spinal column has been well defined in an optimized view phantom neck<sup>55</sup>. The superb photos in the publication represent unrealistic good images, that could never be replicated in real patients. No-one has however, yet devised a real-time ultrasound guided midline needle technique. This author thinks that is impossible, and if possible, would likely not improve the current techniques used.

#### 9. INSERTING TOUTHY NEEDLE HIGH-MID THORACIC, AND FEEDING THE CATHETER UP TO CERVICAL LEVEL.

This technique was described a few times by Ban Tsui<sup>56, 57, 58</sup>. Tsui had an interest in stimulating epidural catheters. He first used standard epidural

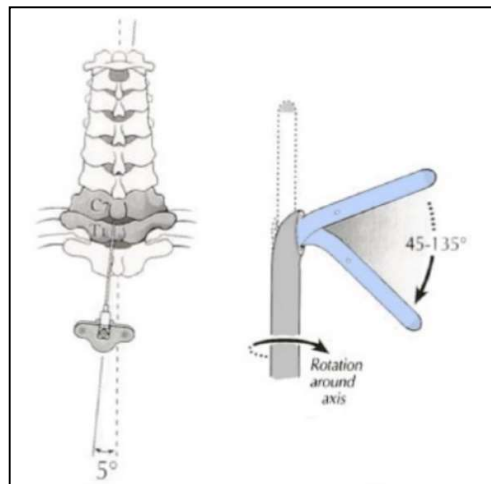
catheters with column of saline fluid and a Johan's adapter to conduct the current to the tip of the catheter. Later he used the Arrow Flexi-tipR styletated epidural catheter in similar style. This never became popular due to inconsistent ability to achieve a high positioned catheter, that stayed in the dorsal midline. It was also time consuming and needed radiological confirmation.

This is not a recommended routine method, at all. The only advantage of inserting the needle many segments lower than the targeted segment level for the final position of the epidural catheter, as that if a needle-cord injury occurs it is well caudad to the upper limb and diaphragm responsible cord segments. This author has experience with stimulating epidural catheter techniques.

# 10. DIRECTING THE CATHETER TOWARDS ONE SELECTED (LATERAL) SIDE.

A drawback of using a cervical epidural block inserted for anesthesia and analgesia of one limb, is that the contralateral healthy limb is anesthetized too. That limits the patient's ability to use that hand for general purposes. One remedy has been proposed, namely of redirecting the catheter towards the therapy-side of the spinal canal.

Insert the epidural in the midline as is conventional. After the needle tip has penetrated the epidural space tilt the needle 5 degrees to lateral away from the surgical side, so as for the needle tip to point slightly towards the surgical target side. In addition, rotate the angled Tuohy needle-tip orifice 90 degrees so that it faces lateral, towards the target therapy side of the patient. Next advance the catheter out of the needle and continue as is routine. Buchheit<sup>59</sup>, was able to achieve a clinically lateral epidural block in 29 out of 30 study patients.



**General comments;** With cervical epidural blocks, it is common to get some minor radiating *discomfort* into one of the arms during insertion and block initiation. This can be ignored, provided it is not excruciating. Excruciating pain demands removal of the catheter. A lancing injury to the spinal cord is suggested if a very vaguely described sensation discomfort is reported going down the back, to areas below the cervical dermatomes in a fully unsedated patient. Most patients usually would not be able to report feeling penetration of the cord. If penetration of the cord is suspected, this requires removal of the catheter or needle. Do not inject contrast for an X-ray for verification, if cord penetration is suspected. Contrast injected into the cord is damaging regardless of the type of contrast used. The best test for whether a Touhy needle has penetrated the cord, is to see if an ultra-soft-tip catheter can be easily passed 3 or more centimetres beyond the needle tip.

Discomfort down the back may also be possible with a subarachnoid catheter that has turned downwards. CSF aspiration should confirm that. Remove the catheter. *In summary, mild discomfort in the arms is acceptable, but any discomfort below the neck is unacceptable.*

In general, the cervical epidural block is a very easy epidural block to carry out. In the era prior to ultrasound guidance being established in regional anesthesia usage, some practitioners found placing cervical epidural catheters easier and more reliable than placing blind interscalene catheters. That is no longer true and all interscalene plexus catheters should be only be placed using ultrasound guidance, unless the operator is mature and very well experienced with non-ultrasound guided regional anesthesia techniques.





## LOCAL ANESTHETIC DOSES for CERVICAL EPIDURAL BLOCKS.

A variety of local anaesthetic drugs have been used. Bupivacaine 0.5% has been used for neck block dissections, upper thoracic surgery, breast surgery. Mepivacaine 1% has been used<sup>60</sup>. Lignocaine 2% has been much studied. Volume is important and drug dose and concentration is lesser, but still significant importance. One approximate *rule of thumb* is that epidural drugs spread 1.5 ml per segment in the lumbar region, 1 ml per segment in the thoracic segments and 0.5 ml per segment in the cervical segments for when using 0.5% Bupivacaine.

Visser<sup>61</sup> did a cervical epidural study administering 3 ml of 2% lignocaine. The block spread 1.8 segments per ml at C7-T1, 1 segment per ml at T3-5, and 2.3 segments per ml at T7-9 on average. In particular the higher epidural injection sites demonstrated the feature of a disproportionate greater downward drug spread than upwards. This emphasised that the catheter tip must lie epidurally in the upper portion of the dermatomes requiring blockade, especially in the higher thoracic regions. Drug absorption from the cervical epidural space was shown by Mayumi to be the same when he injected 10 ml of 2% lignocaine in different groups in the cervical, midthoracic and lumbar regions<sup>62</sup>. Ropivacaine due to its feature of preserving motor function best of all local anaesthetics, seems the wisest choice of drug in cervical epidural anaesthesia.

Jain in a randomized prospective trial of 74 patients undergoing awake thyroidectomy studied three local anesthetic drugs<sup>63</sup>. The drugs studied were 1% lignocaine (lidocaine), 0.25% bupivacaine, and 0.5% ropivacaine. All drugs were broadly satisfactory and usable. The 0.5% ropivacaine gave the most motor block in the arms, and the 1% lignocaine needed frequent top-up injections.

For anaesthesia (for surgery) this author has found 0.375% to 0.4% Bupivacaine, or Ropivacaine 0.4 to 0.5% very satisfactory. For analgesia the author uses 0.2 to 0.25% Bupivacaine or Ropivacaine 0.25%. A volume of 5 to 7 ml is satisfactory usually. It has been the lecturer's experience that those doses cause no clinical ventilatory problems, and only minimal hand weakness sometimes, but very reliable analgesia. More dilute solutions result in incomplete analgesia occasionally. Infusions can be run at rates between 4 and 8 ml per hour. Ropivacaine 0.2% is a good infusion drug. If one hand is weaker than the other and it is disturbing the patient, the problem can usually be remedied by withdrawing the epidural catheter slightly, for 1 to 2 cm. It is probable the catheter-tip was lying off the midline, and closer to the side most affected.

The Lecturer never uses epidural opiates because of the proximity to the brain stem and probable greater potential for central side effects from upwards drug drift that absorbed into the CSF. Including fentanyl 25 -40µg is acceptable.

### AUTHOR'S RECOMMENDATION:

For surgical indications, regardless of whether the patient is receiving a simultaneous general anesthetic or being kept awake is use **0.4% ropivacaine**. Estimate the required drug volume at 1ml per segments needed to be blocked. Predict the segmental spread to be upwards by one segment less than the downwards spread.

For postoperative infusions run **0.2% ropivacaine** at flow rates of 4 to 8 ml/hour.



## LOCAL ANESTHETIC TOXICITY and CERVICAL EPIDURALS

Significant local anesthetic toxicity is very rarely observed with cervical epidural blocks. Published cases are very rare, and unclear.

This author reports a personal CASE experience: A patient, an ASA1 healthy fasted female of 20 years age, was in the upright sitting position. The Tuohy needle was being inserted in the midline via the C7-T1 spinous process interspace. All aspects of the procedure proceeded smoothly, as per routine and expectations. The advancing needle felt a slight increase in resistance to advancement, at a depth where the ligamentum flavum was expected. The needle was slowly advanced further, through the ligamentum flavum. A subtle snap was next felt with a sudden loss of resistance to the injection of saline following the snap. Approximately 1 ml of saline was injected in that loss of resistance moment. The original plan was to disconnect the syringe from the Tuohy needle, and pass an ultra-soft-tip catheter via which to inject the block drugs. As the syringe was separated from the needle, a drop of residual saline in the hub of the back of the needle sucked inwards. It fascinated the doctor, who placed another drop of saline in the hub which sucked in again. This enchanted the doctor who took a snap decision to inject the main dose of drug via the needle, rather than via the catheter that was still to be passed. Five millilitres of 0.4% Ropivacaine, totalling 20 mg ropivacaine was injected. Before the syringe could be disconnected from the needle, the patient started to convulse.

The patient was immediately laid horizontal on the surgical table and intubated with commencement of sevoflurane general anesthesia. The convulsions stopped within 2 minutes. The surgery, thoracoscopic bilateral upper thoracic sympathectomy for sweaty hands, was uneventfully completed within 90 minutes. The patient woke up as if all was normal, but had no analgesia from the nerve block. The postulate is that the epidural needle tip had punctured an epidural vein, and the injected drug was pushed into that vein. Epidural veins are valve-free, and in direct continuity with cerebral veins. The injected drug was infused retrograde, under injection pressure, direct to the brain undilute, identical to how it would have been if injected via the carotid artery. This would explain why such a tiny dose of ropivacaine could cause convulsions. The sucking in of the drops of saline within the needle hub can be explained by the probability that the venous pressure was likely sub-atmospheric, at the height of the epidural block level, above the level of the heart in a sitting healthy fasted patient.

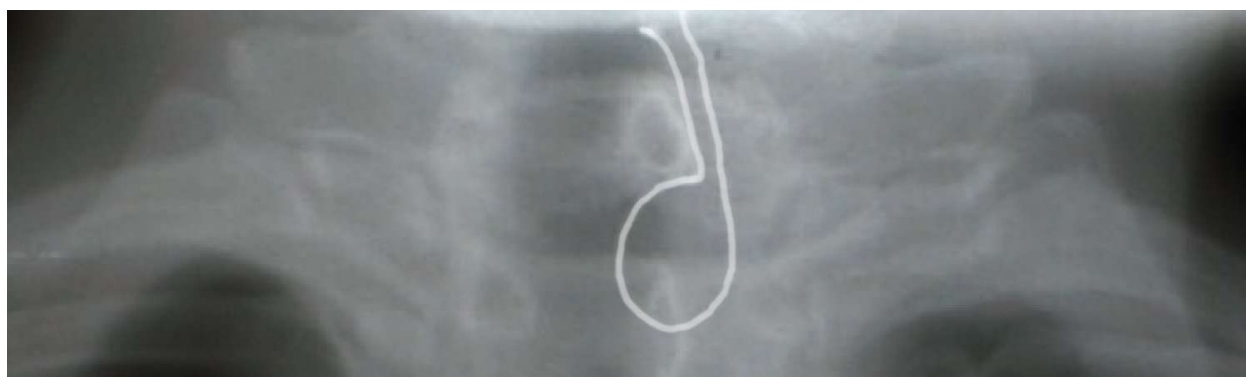
The additional lesson to be learned is that the drug should not have been injected prior to first doing an aspiration test to the needle (or catheter). An aspiration test would highly likely have revealed the needle tip was intravenous.

A similar case has been reported where following injection of only 12.5 mg of levobupivacaine for a cervical epidural block, convulsions resulted<sup>64</sup>. In one other 131kg male only 2ml of 2% lidocaine (40mg lidocaine in total) was injected supposedly transforaminal cervical epidural<sup>65</sup>. The patient immediately became unresponsive, briefly convulsed, and regained normal status within 20-minutes. His blood lidocaine levels were later too low to be measurable. It was also postulated to have resulted from an unrecognized intravenous injection with retrograde direct and undiluted to the brain.



## CONCLUSION

Cervical epidural analgesia is technically easy to do. It is far easier to do, for example, than catheterising the interscalene and axillary brachial plexus using old blind-techniques (without ultrasound). Epidural anaesthesia is easy to maintain by infusion. Postoperative infusion is always an attractive therapeutic modality because of the ease with which it can be maintained for days via a catheter. Cervical epidural anaesthesia also provides predictable and reliable nerve blockade. Potential applications are diverse and acquiring skill and confidence in the technique, can be valuable. In good hands the complication risk, despite conceptual fears, seems very low. The procedure is a specialised technique and should only be done by fully qualified physician anaesthesiologists already very competent in lumbar epidural anaesthesia<sup>5</sup>.



This author has no trade conflicts of interest related to scientific writing and teaching, to declare at time of writing.

This author takes no responsibility for other person having medical mishaps based upon the content of this lecture. The lecture was prepared with best intentions and honest best research, and in context of personal medical experience. The reader is solely responsible for their own medical practice

---

<sup>1</sup> Wittich DJ, et al. Cervical epidural for head and neck surgery. *Laryngoscope*, 94:615, 1984.

<sup>2</sup> Lirk P. Cervical and high thoracic ligamentum flavum frequently fails to fuse in the midline. *Anesthesiology* 2003;99:1387-1390

<sup>3</sup> Aldrete JA. Skin to cervical epidural space distances.... *J Clin Anesth* 1998 Jun, 10:4, 309-13.

<sup>4</sup> Lin CH, Distance from the skin to the cervical epidural space. Sep 1995, *Acta Anaesthesiol. Scand.* 33:3, 161-4.

<sup>5</sup> Santhanna H, et al. Cervical epidural analgesia in current anaesthesia practice: systematic review of its clinical utility and rationale, and technical considerations. *BJA* 2016;116(2):192-207.

<sup>6</sup> Mantha S, et al. Cervical epidural block in emergency hand surgery for a patient with severe untreated severe hypothyroidism. *J Anesth Clin Pharm.* 2015;31(3):424-425

<sup>7</sup> Mahoungou GKC, et al. [Interest of cervical epidural anesthesia in perioperative management of thyroidectomy with the high-risk anesthetic patient.][French] *Ann Fr Anesth Reanim* 2014;33(3):185-6

<sup>8</sup> Khanna R, et al. Cervical epidural anaesthesia for thyroid surgery. *Kathmandu Med J.* 2009;7(27):242-245



- <sup>9</sup> Narouze SN, et al. Continuous cervical epidural analgesia for rehabilitation after shoulder surgery: a retrospective evaluation. *Pain Physician*. 2009;12(1):189-194h
- <sup>10</sup> Noyan A, et al. Continuous cervical epidural anesthesia in hand surgery. *J Reconstr Microsurg*. 2001;17(7):483-485
- <sup>11</sup> Kainuma M. Cervical epidural anaesthesia in carotid artery surgery. *Anaesthesia*, 1986 Oct, 41:10, 1020-3
- <sup>12</sup> Musinu C, et al. Continuous cervical epidural with ropivacaine in carotid surgery. Description of a case. *Minerva Anesth*. 1998;64(12):575-580
- <sup>13</sup> Rowlingson JC. Epidural analgesic techniques in the management of cervical pain. 1986 Sep, *Anesth Analg* 65:9,938-42.
- <sup>14</sup> Jakobsen CJ. High thoracic epidural in cardiac anesthesia. *Seminars in Cardiothoracic and Vascular Anesthesia*. 2015;19(1):38-48
- <sup>15</sup> Green CR. Cervical epidural analgesia for management of pain associated with digital vasculitis secondary to rheumatoid arthritis. *Reg Anesth*. Mar 1997, 22:2,188-91
- <sup>16</sup> Martelletti P. Epidural corticosteroid blockade in cervico-genic headache. *Eur Rev Med Pharmacol Sci*, 1998 Jan, 2:131-6.
- <sup>17</sup> Dahm P. High thoracic/low cervical, long term intrathecal infusion of Bupivacaine alleviates “refractory” pain in patients with unstable angina. *Acta Anaesthesiol Scand*. Sep 1998. 42:8, 1010-7.
- <sup>18</sup> Gramling Babb. Treatment of medically and surgically refractory angina pectoris with high thoracic epidural analgesia: initial clinical experience. Jun 1997, *Am heart j*, 133:6, 648-55
- <sup>19</sup> Mukaido T. Thoroscopic operation for secondary pneumothorax under local and epidural anesthesia in high risk patients. 1998 Apr, 65:4, 924-6.
- <sup>20</sup> Mineo TC. Epidural anesthesia in awake thoracic surgery. *Eur J Cardio-Thor Surg*. 2007;32:13-19
- <sup>21</sup> Stav A. Cervical epidural steroid injection for cervicobrachialgia. *Acta Anaesthesiol Scand*. Aug 1993, 37:6, 562-6
- <sup>22</sup> Veyckemans F. Cervical epidural for cancer child at home. 1994. *Med Paediatr Oncol*, 1994 22:1, 58-60
- <sup>23</sup> Catchlove RF. The use of cervical epidural nerve blocks in the management of chronic head and neck pain. Mar 1984, *Can Anaesth Soc J*. 31:2, 188-191.
- <sup>24</sup> Dohi S. Circulatory responses to airway stimulation and cervical epidural blockade. Nov 1982. 57:5, 359-63
- <sup>25</sup> Takeshima R, et al. Cervical epidural block and surgical blood loss in radical mastectomy. *Regional Anesthesia* Oct-Dec 1986;11:171-175
- <sup>26</sup> Takeshima R, et al. Cervical epidural block and surgical blood loss in radical mastectomy. *Regional Anesthesia* Oct-Dec 1986;11:171-175
- <sup>27</sup> Kim JY, et al. Analgesic efficacy of two interscalene blocks and one cervical epidural block in arthroscopic rotator cuff repair. *Knee Surg Sports Trauma Arthrosc*. 2016;24(3):931-9
- <sup>28</sup> Wenk M, et al. Feasibility of cervical epidural anesthesia for breast cancer surgery. *Anesth Research Practice* 2017; ID7024924, web published. 5 pages
- <sup>29</sup> Paliwal B, et al. Off-pump awake coronary artery bypass grafting under high thoracic epidural anesthesia. 2016 *Journal of Anesthesiology clinical Pharmacology*. 2016 Apr-Jun;32(2):261-2 [www.joacp.org](http://www.joacp.org) DOI: 10.4103/0970-9185.168201
- <sup>30</sup> Merquiol F, et al. Cervical epidural anesthesia is associated with increased cancer-free survival in laryngeal and hypopharyngeal cancer surgery: a retrospective propensity-matched analysis. *RAPM* 2013;38(5):398-402.
- <sup>31</sup> Tagariello V Et al. Diaphragmatic motion and respiratory function during cervical epidural anaesthesia (CEA). *Regional Anesthesia* 1996;21(4):p384
- <sup>32</sup> Sheikh T, et al POSTER. Does cervical epidural anesthesia affect pulmonary function? *RAPM* 1997
- <sup>33</sup> Sheikh T, et al. Time course of the effects of cervical epidural anesthesia on pulmonary function. *RAPM* 1998;23(1):20-24
- <sup>34</sup> Capdevilla X. The effects of Cervical Epidural Anaesthesia with Bupivacaine on Pulmonary function in Conscious Patients. *Anaesthesia and Analgesia*. 86:5,1033-8. 1998.
- <sup>35</sup> Nystrom UM. Continuous Cervical Epidural Anesthesia in Reconstructive Hand Surgery. *J Hand Surg*. 1997 Sep, 22:5,906-12
- <sup>36</sup> Stevens RA; Time course of the effects of cervical epidural anesthesia on pulmonary function. *Reg Anesth Pain Med*, 1998 Jan, 23:1,20-4
- <sup>37</sup> Huang CH. Effect of cervical epidural blockade with 2% lidocaine plus epinephrine on respiratory function. *Acta Anaesth Taiwan* 2007;45(4):217-22
- <sup>38</sup> Wittich DJ, et al. Cervical epidural for head and neck surgery. *Laryngoscope*,94:615, 1984.
- <sup>39</sup> Williams KN. Epidural hematoma requiring surgical decompression following repeated cervical epidural steroid injections for chronic pain. Aug 1990. *Pain* 42:2, 197-9
- <sup>40</sup> Samali M, et al. Anesthetic management of spontaneous cervical epidural hematoma during pregnancy: a case report. *J Med Case reports*. 2017;11(171) DOI 10.1186/s13256-017-1335-y Web published
- <sup>41</sup> Kumchev YN, et al. Spontaneous cervical epidural hematoma. A case report. *Folia Med (Plovdiv)* 2010. 52(2):64-67





- <sup>42</sup> Taha MM, et al. Spontaneous cervical epidural hematoma: a case report and review of the literature. *Surgical Neurology International* 2019;10(147): on line
- <sup>43</sup> Banik RK, et al. Spinal epidural hematoma after interlaminar cervical epidural steroid injection. *Anesthesiology* 2019. 131;(6):1342-1343
- <sup>44</sup> Ememhadi M, et al. Spontaneous cervical epidural hematoma with stroke manifestations. *Asian J Neurosurg* 2018;14(1):286-288
- <sup>45</sup> Jusue-Torres I, et al. [Iatrogenic cervical epidural hematoma: case report and review of the literature] [Spanish] *Neurocirugia (Astur)* 2011;22(4):332-336
- <sup>46</sup> Mehta N. Intracranial hemorrhage and pneumocephaly after cervical epidural injection. *Clin Prac Cases Emerg Med* 2019. II(4):369-371
- <sup>47</sup> Field J, et al. Neuropathic pain following cervical epidural steroid injection. *Anesthesiology* 2000;93:885-888
- <sup>48</sup> LeFavre J, et al. Upper cervical epidural abscess resulting in respiratory compromise after lumbar epidural steroid injection. *J Emerg Med* 2019 Jul;57(1):66-69
- <sup>49</sup> Hodges SD. Cervical epidural steroid injection with intrinsic spinal chord damage. *Spine*, 1998 Oct. 23:19, 2137-42: discussion 2141-1.
- <sup>50</sup> Giebler RM, Incidence of neurological complications related to thoracic epidural catheterisation. *Anaesthesiology*, Jan 1997, 86:1, 55-63
- <sup>51</sup> Colonna-Romano P, et al. Cervical dural puncture and lumbar extra-dural blood patch. *Can J Anaesth* 1995;42(12):1143-1144
- <sup>52</sup> Bao C, et al. Hemorrhagic infraction of cerebellum and brainstem due to cervical epidural steroid injection - case report and review of the literature. *Acad Forensic Pathol.* 2018;8(4):952-956
- <sup>53</sup> Leon-Casasola LA. Transforaminal cervical epidural injections. *RAPM* 2008;33(2):190-193
- <sup>54</sup> Cousins MJ. Book. Neural Blockade, in clinical anesthesia and management of pain., Lippincott-Raven 1998.ISBN 0-397-51159-0.
- <sup>55</sup> Eerd M, et al. Ultrasonography of the cervical spine. *Anesthesiology* 2014;120:86-96
- <sup>56</sup> Tsui BCH, et al. Cervical epidural analgesia via a thoracic approach using nerve stimulation guidance in an adult patient undergoing elbow surgery. *RAPM* 2004;29:355-360
- <sup>57</sup> Tsui BCH, et al. Dextrose water in water: fluid medium for maintaining electrical stimulation of peripheral nerves during stimulating catheter placement. *Acta Anaesth Scand* 2005;49:1562-1565
- <sup>58</sup> Tsui BCH, et al. Cervical epidural analgesia via a thoracic approach using nerve stimulation guidance in adult patients undergoing total shoulder replacement surgery. *Acta Anaesth Scand* 2007;51(2):255-260
- <sup>59</sup> Buchheit T, et al. Lateral cervical epidural catheter placement for continuous unilateral upper extremity placement for continuous unilateral upper extremity analgesia and sympathetic block. *RAPM* 2000;25:313-317
- <sup>60</sup> Higa K, High thoracic epidural block relieves acute herpetic pain involving Trigeminal and cervical regions: comparison with Stellate ganglion block.
- <sup>61</sup> Visser WA; Extension of sensory blockade after thoracic epidural test dose of lignocaine. 1998 Feb, 86;2,332-5
- <sup>62</sup> Mayumi T, Plasma concentrations of lidocaine associated with cervical, thoracic and lumbar epidural anesthesia. *Jun* 1983, 62:6, 578-80
- <sup>63</sup> Jain G, et al. Comparison of three formulations of local anaesthetics for cervical anaesthesia during thyroid surgery. *Indian J Anaesthesiology.* 2012;50(2):129-134
- <sup>64</sup> Kang HY, et al. An unusual delayed onset of systemic toxicity after fluoroscopy guided cervical epidural steroid injection with levobupivacaine: A case report. *Pain Practice* 2019;19(7) papr.12802 (on line)
- <sup>65</sup> Powell AEC, et al. Convulsion and atrial fibrillation after transforaminal cervical epidural lidocaine injection. *Clin Prac Cases Emerg Med.* 2018. II(4):344-347.

This material **Copyright is owned by Regional-Anesthesia.Com LLC**, 2177 Port Talbot Place, IA51141, USA. It may be printed for free by one individual, for that single individual use.

If any institution, company or body wishes to print this material in numbers more than one, or any other material to be found at [www.regional-anesthesia.com](http://www.regional-anesthesia.com), or distribute it in any digital format, it must please contact the Editor of Regional-Anesthesia.Com and make a financial offer. The fee will be variable based upon country size, the size of the institution or body, and whether the institution, body or group are charging fees to the persons to receive the material. Strong consideration will be given to the proposed fee.

**Regional-Anesthesia.Com LLC** does have an altruistic primary goal of education and advancing patient care via regional anesthesia. **Regional-Anesthesia-Com LLC** however, has limited income sources to sustain its continuance and needs donations, advertising fees, and royalty payments.